

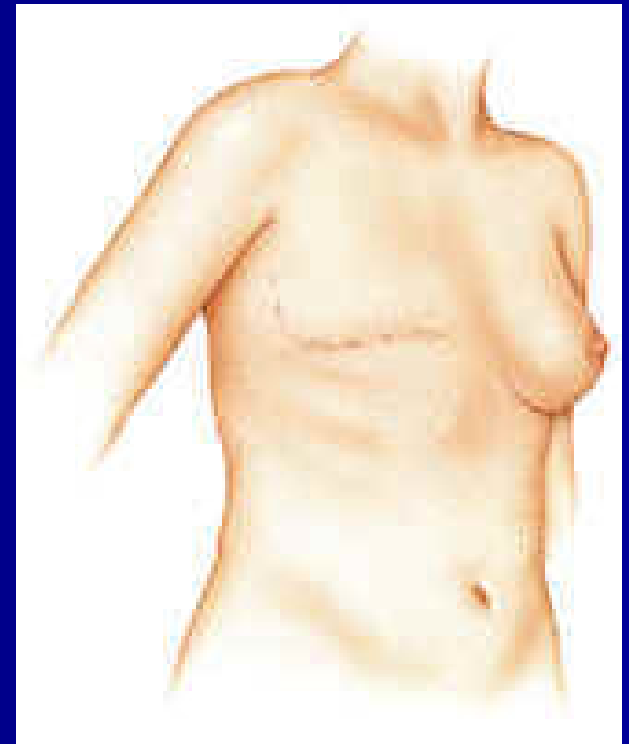Modified Radical Mastectomy

Pornchai O-charoenrat MD PhD

Professor
Division of Head, Neck & Breast Surgery
SIRIRAJ HOSPITAL
THAILAND

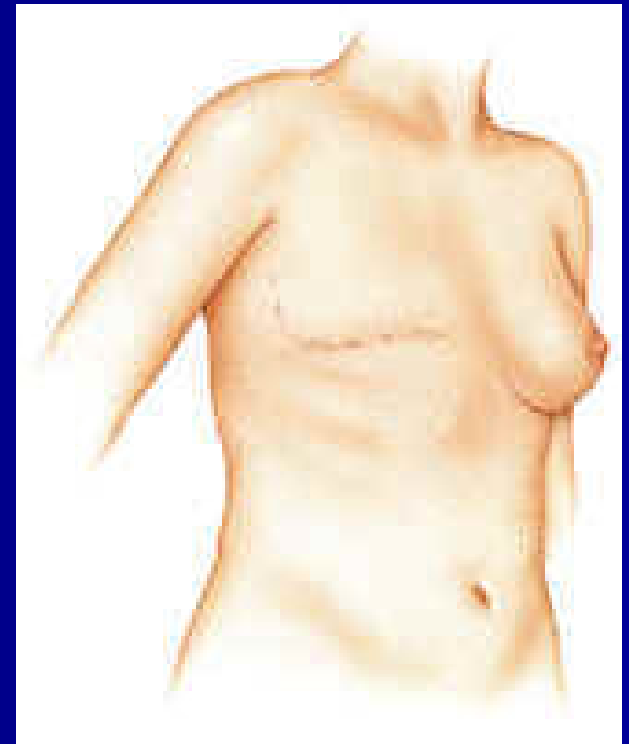
Modified Radical Mastectomy (MRM)

- Rationale
- Indications
- Techniques
- Special considerations



Modified Radical Mastectomy (MRM)

- Rationale
- Indications
- Techniques
- Special considerations



Mastectomy

'Surgical Removal of the Breast'

Radical mastectomy – removal of the breast, pectoralis major and minor m. and Level I-III axillary nodes

Modified radical mastectomy – removal of breast and Level I or Level I and II nodes

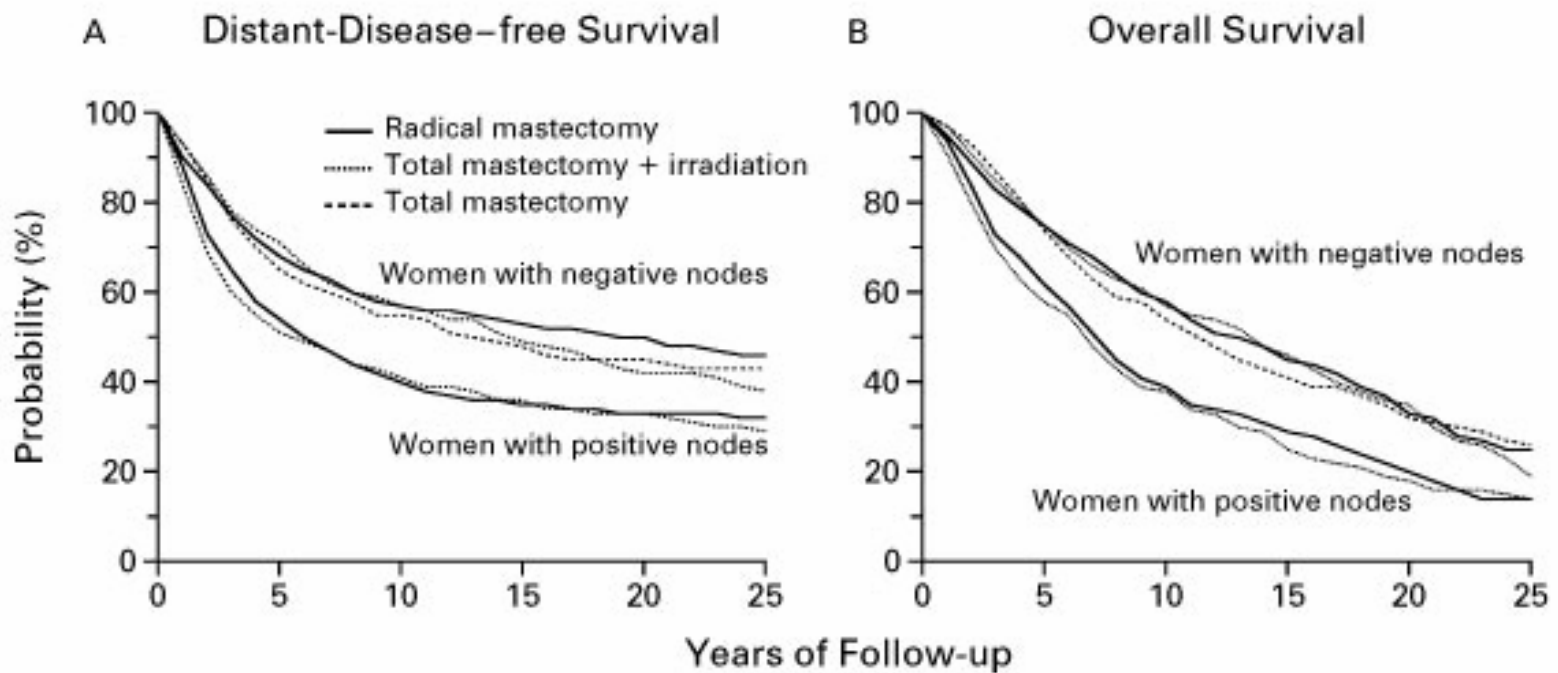
Simple mastectomy – removal of breast

Skin-sparing mastectomy – mastectomy with removal of nipple-areolar complex, but with preservation of the rest of the breast skin

NSABP-B04 Study

- ❑ Dissatisfaction with results after radical mastectomy
- ❑ Less radical surgery might be just as effective as the more extensive operations
- ❑ To determine whether patients who received local or regional treatments other than radical mastectomy would have outcomes similar to those achieved with radical mastectomy

Radical Mastectomy Offers No Advantage



Fisher et al. *NEJM* 2002

Modified Radical Mastectomy (MRM)

Advantages over radical mastectomy

- ❑ Good postoperative cosmetic appearance
- ❑ Maintain motor activity in the arm
- ❑ Low rate of postoperative arm edema
- ❑ Easy postoperative breast reconstruction

Modified Radical Mastectomy (MRM)

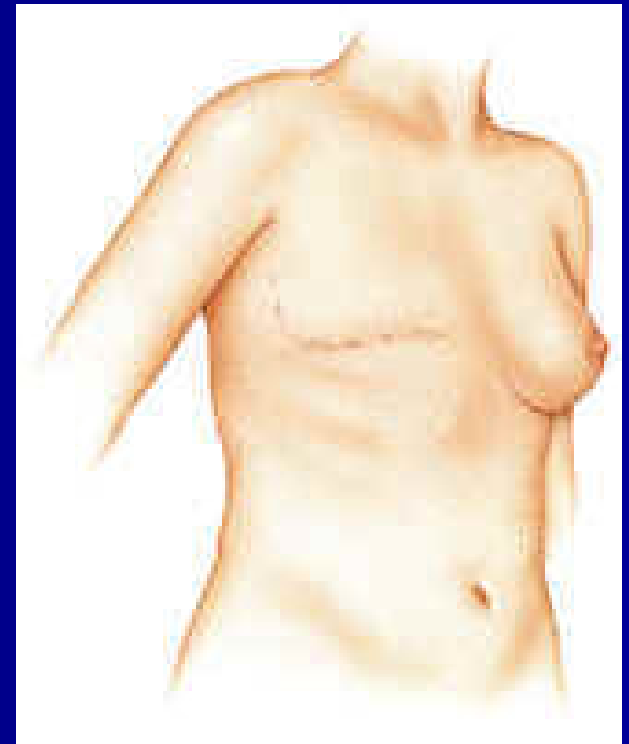
Patey: removal of pectoralis minor muscle to allow Level III node dissection

Madden and Auchincloss: preservation of both pectoralis major and minor; only level I-II dissection

- Higher chance of medial pectoral nerve preservation
- Reduce arm swelling

Modified Radical Mastectomy (MRM)

- Rationale
- **Indications**
- Techniques
- Special considerations



Patient Selection and Evaluation

- History and physical examination
- Mammography
- Histological assessment of the resected breast specimen
- Assessment of the patient's needs and expectations

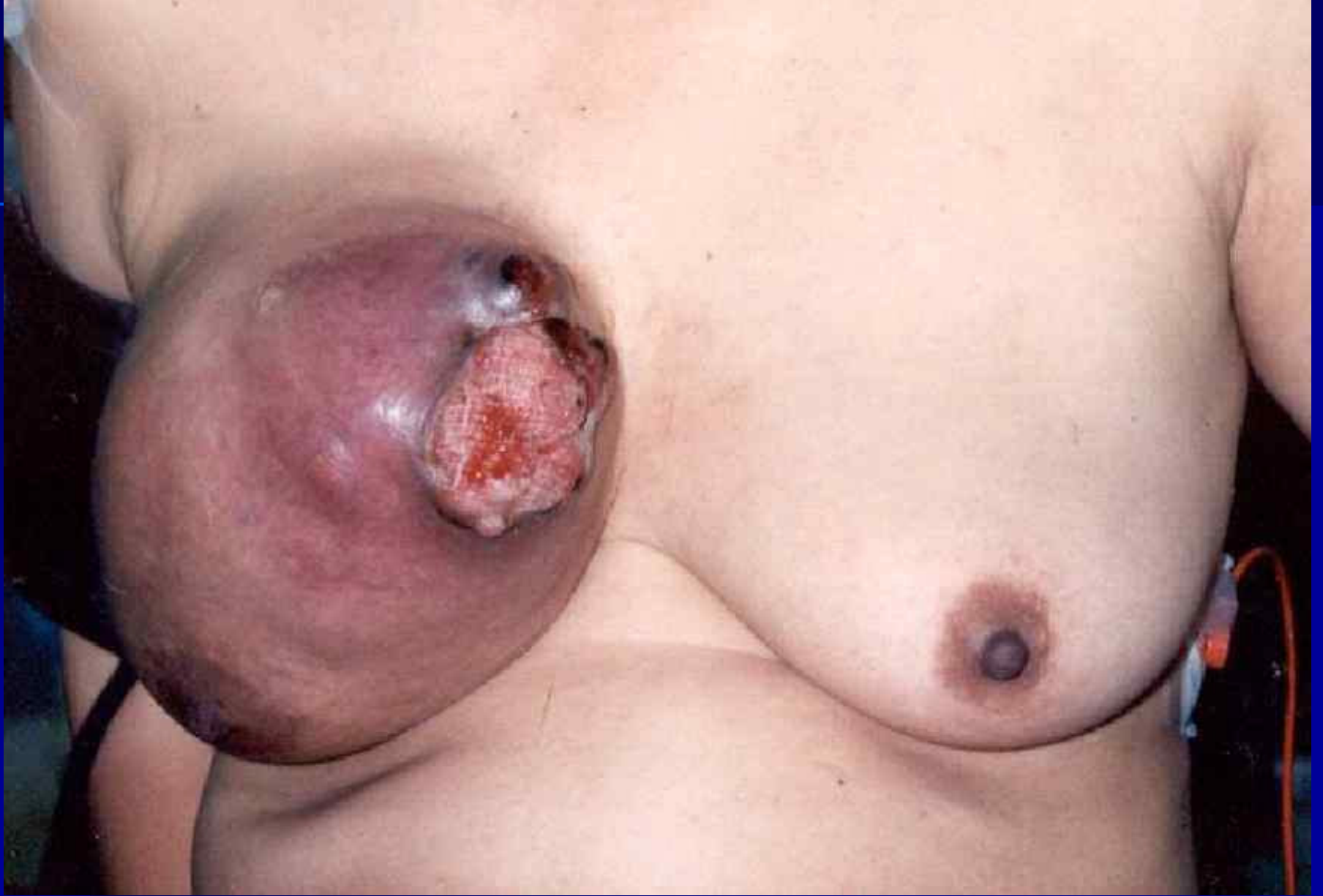Absolute Indications for Mastectomy

= Absolute contraindications for BCT

- Multicentricity or diffuse malignant-appearing microcalcifications
- Persistent positive margins after reasonable surgical attempts
- History of prior therapeutic irradiation to the breast region
- Pregnancy (first or second trimester)

Relative Indications for Mastectomy

- Large tumor in a small breast
- Tumor size (> 4-5 cm)
- Breast size (large or pendulous breasts)
- History of collagen vascular disease (scleroderma or active SLE)
- Multifocality



? Indications for Mastectomy

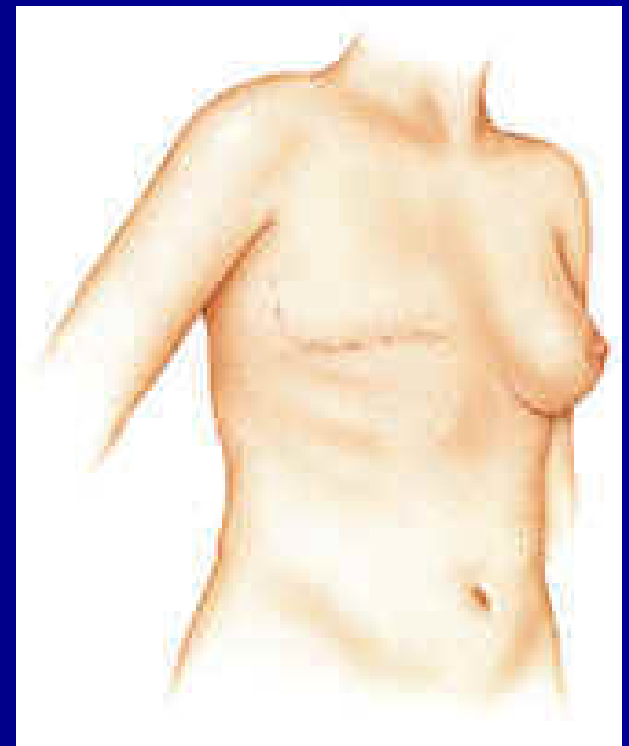
- ❑ Prophylactic mastectomy for familial or high risk women
- ❑ Cost and inconvenience of irradiation
- ❑ Attitude of patient/relatives/friends
- ❑ Because the doctors say so

Because the doctors say so

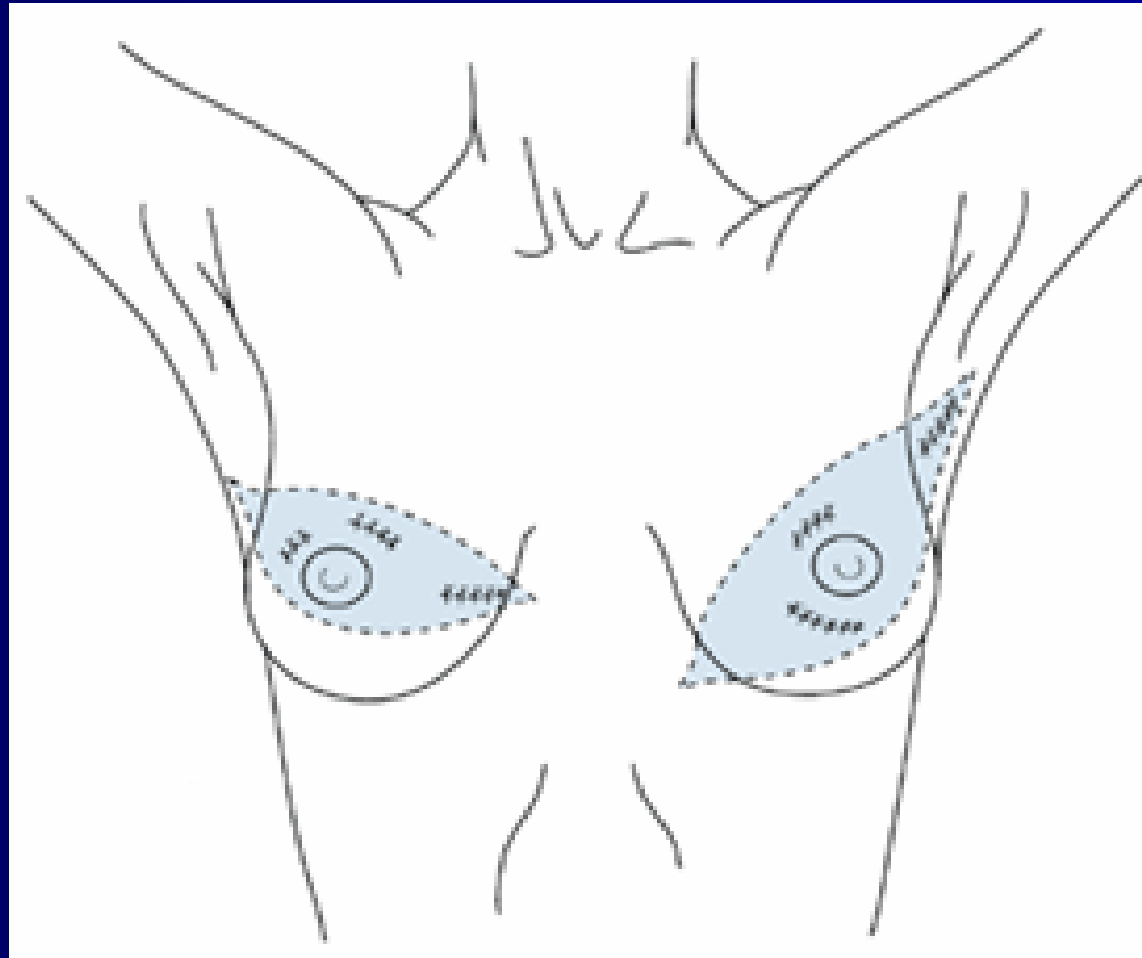
- ❑ 29 percent of patients had been offered only the option of a mastectomy
- ❑ All were from a metropolitan area
- ❑ 70 percent had more than a high-school education
- ❑ 62 percent reported an annual family income of more than \$30,000
- ❑ More than 90 percent had health insurance

Modified Radical Mastectomy (MRM)

- Rationale
- Indications
- **Techniques**
- Special considerations



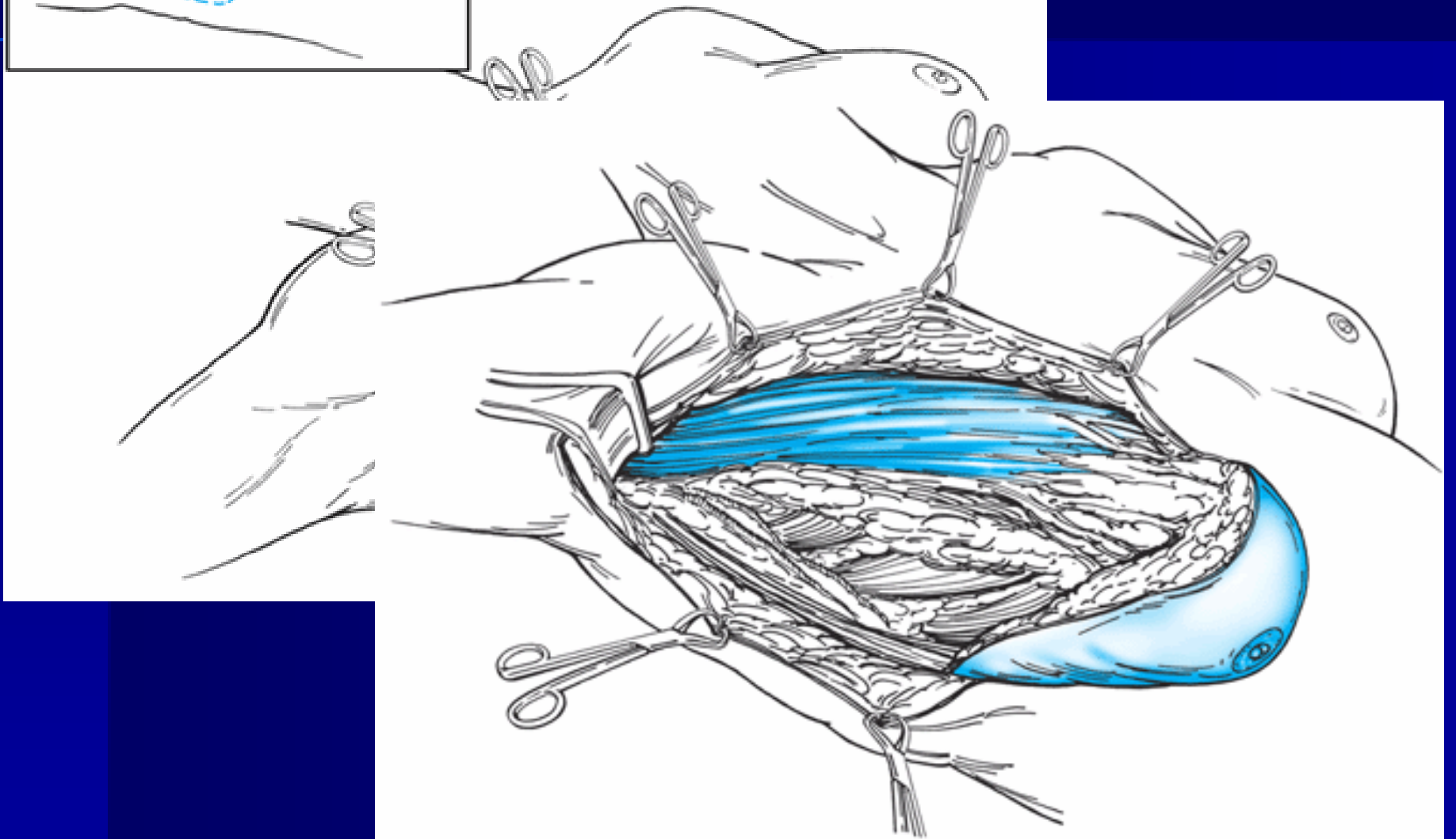
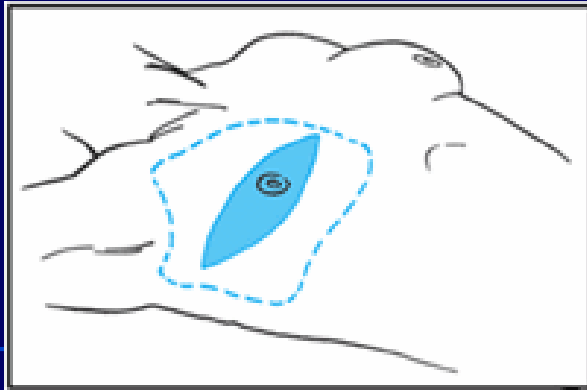
Skin Incision

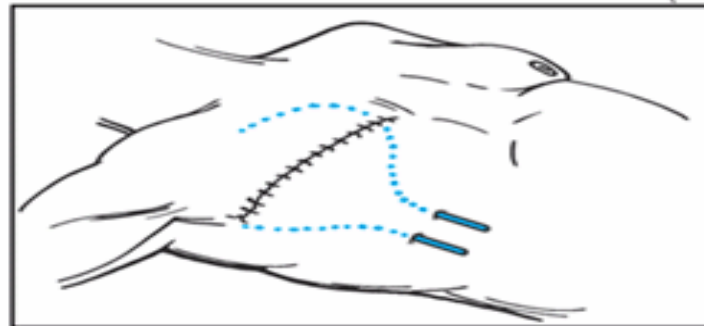
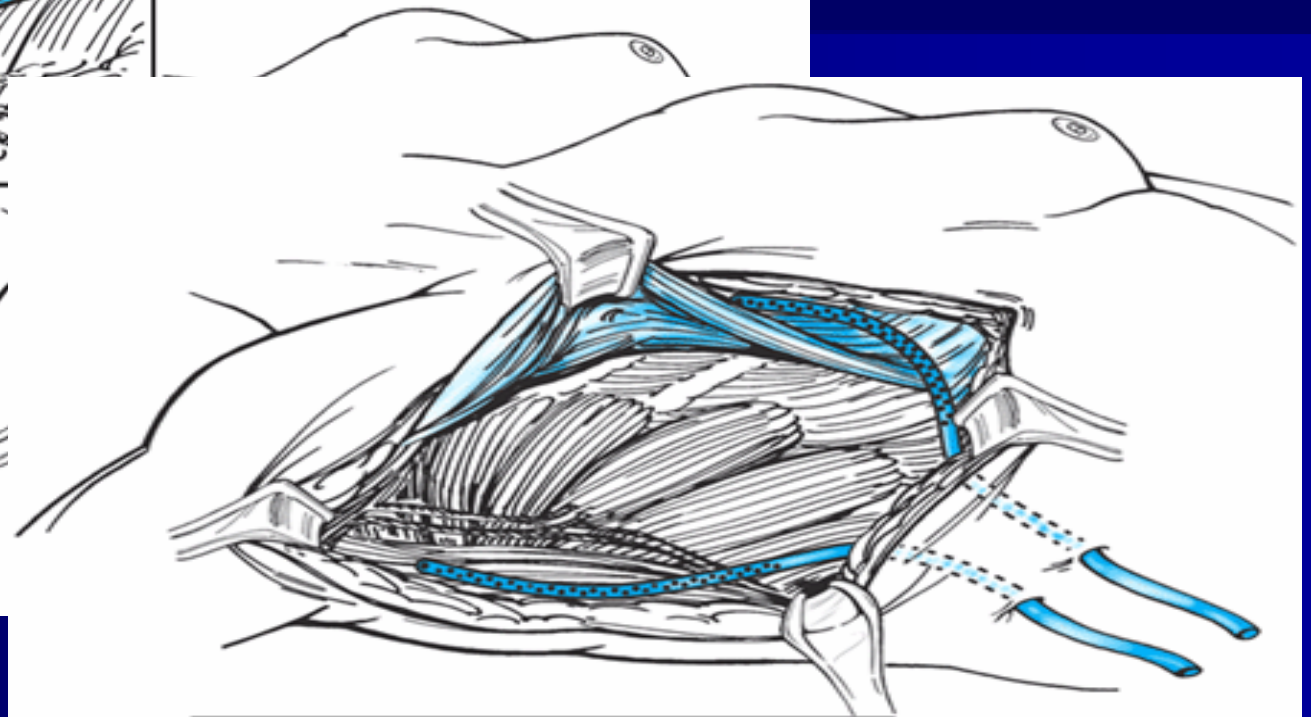
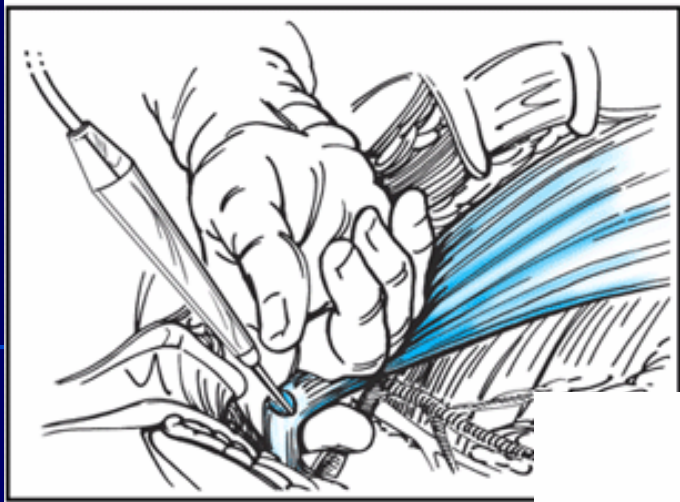


Modified Radical Mastectomy (MRM)

'Total mastectomy with *en bloc* removal of breast tissue, pectoralis fascia, nipple/areolar complex, axillary lymphatics, and overlying skin near the tumor with a 2-cm margin'

Preservation of pectoralis major muscle



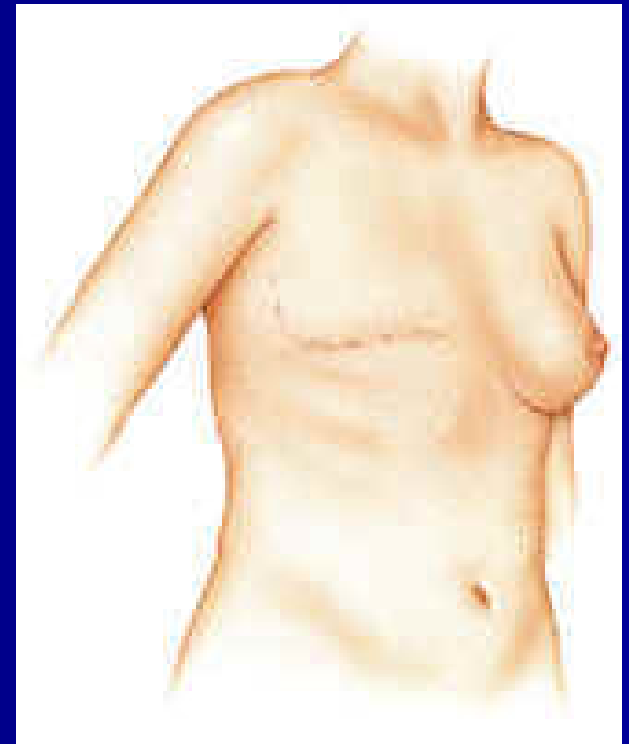


Anatomic Boundaries of MRM

- ❑ Lateral - anterior margin of latissimus dorsi muscle
- ❑ Medial - midline of the sternum
- ❑ Superior - subclavius muscle
- ❑ Inferior - caudal extension of the breast 2 to 3 cm inferior to the inframammary fold

Modified Radical Mastectomy (MRM)

- Rationale
- Indications
- Techniques
- Special considerations



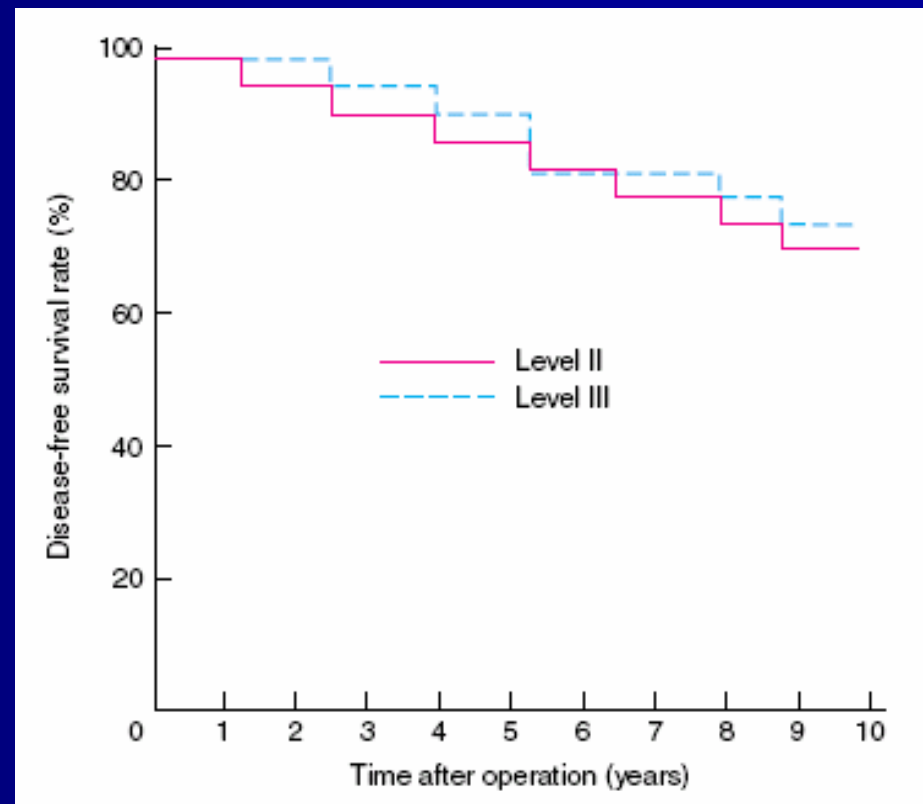
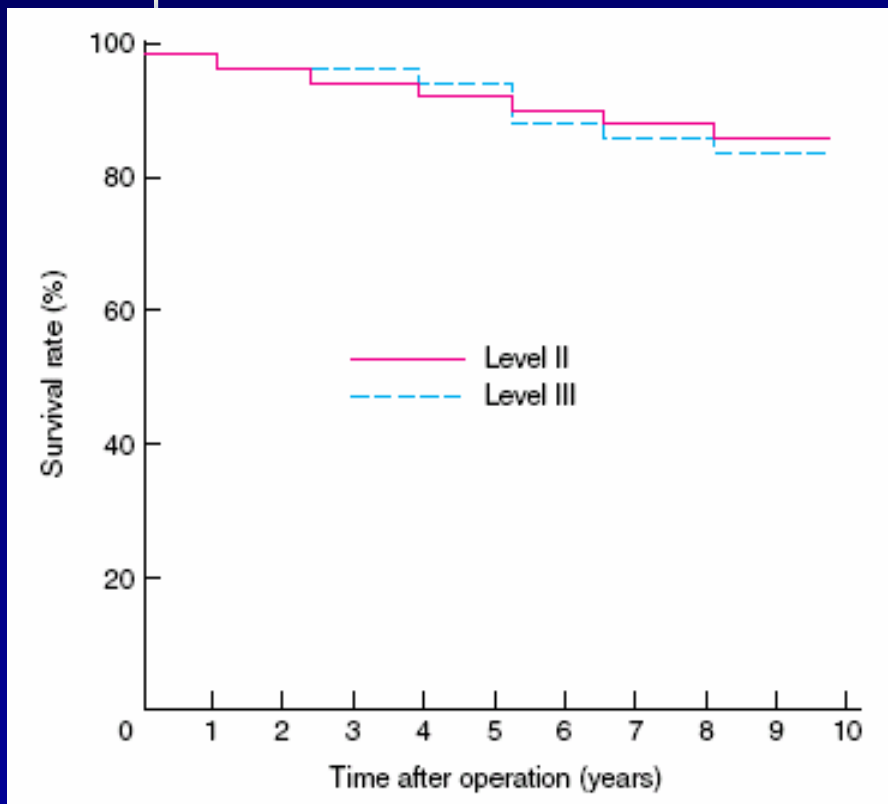
Special Considerations

- Level III dissection
- Intercostobrachial nerve
- Drain or no drain
- Seroma formation

Special Considerations

- Level III dissection
- Intercostobrachial nerve
- Drain or no drain
- Seroma formation

Randomized clinical trial comparing level II and level III axillary node dissection in addition to mastectomy for breast cancer



Special Considerations

- Level III dissection
- Intercostobrachial nerve
- Drain or no drain
- Seroma formation

Long term results of a randomised prospective study of preservation of the intercostobrachial nerve

Table 1 Symptoms of sensory deficit

	Randomised to preserve (n = 39)	Randomised to sacrifice (n = 34)	P	Actually preserved (n = 29)	Actually divided (n = 44)	P
Pain	6 (15)	11 (32)	0.09 n.s.	4 (14)	13 (30)	0.12 n.s.
Normal sensation	10 (26)	8 (24)	0.83 n.s.	10 (34)	8 (18)	0.11 n.s.
Numbness	5 (13)	5 (15)	1.0 n.s.	4 (14)	6 (14)	1.0 n.s.
Diminished sensation	20 (51)	22 (65)	0.25 n.s.	13 (45)	29 (66)	0.07 n.s.
'Different' sensation	17 (44)	20 (59)	0.19 n.s.	9 (31)	28 (64)	0.006

Values in parentheses are percentages.
n.s. = Not significant.

Long term results of a randomised prospective study of preservation of the intercostobrachial nerve

Table 2 Sensory deficits on examination

	Randomised to preserve (n = 39)	Randomised to sacrifice (n = 34)	P	Actually preserved (n = 29)	Actually divided (n = 44)	P
Normal	9 (23)	7 (20)	0.80 n.s.	9 (31)	7 (16)	0.13 n.s.
Total loss	14 (36)	15 (44)	0.47 n.s.	10 (37)	19 (43)	0.46 n.s.
Diminished	18 (46)	19 (56)	0.41 n.s.	11 (37)	26 (59)	0.08 n.s.
Paraesthesia	5 (13)	5 (15)	1.0 n.s.	3 (10)	7 (16)	0.73 n.s.
Total area of abnormal sensation (cm ²)	Median 20 Range 0–100	Median 27 Range 0–360	0.24 n.s.	Median 10 Range 0–100	Median 32 Range 0–360	0.009

Preservation of the Intercostobrachial Nerve

- ❑ Oncological safe
- ❑ Alteration in sensation or presence of pain cannot be solely attributed to preservation or sacrifice of the ICBN
- ❑ Some patients whom had nerve sacrifice had normal sensation and yet many with nerve preservation did not
- ❑ No clear difference in pain

Special Considerations

- Level III dissection
- Intercostobrachial nerve
- Drain or no drain
- Seroma formation

Drain or No Drain

- ❑ Following MRM, standard practice involves insertion of suction drains deep to mastectomy flaps and in the axilla
- ❑ Drains are left in situ until fluid drainage is less than 40-50 ml/day usually 6-14 days after operation
- ❑ Despite the use of suction drains, seromas requiring aspiration still occur in 10-52 percent of patients

Randomized clinical trial of no wound drains and early discharge in the treatment of women with breast cancer

	Mastectomy		Wide local excision	
	Drain	No drain	Drain	No drain
Length of stay (days)*	5.59(1.05, 0.11)	4.18(1.51, 0.16)	4.86(1.16, 0.12)	3.31(0.96, 0.10)
Wound infection‡§	10 (10)	10 (11)	9 (10)	16 (18)
Seroma formation‡	52 (55)	57 (61)	46 (51)	41 (47)
Seroma volume (ml)†	213(41)	184(28)	122(24)	166(19)
Abduction, change from baseline (°)†				
After operation	- 27.9(2.6)	- 29.3(2.1)	- 23.0(2.0)	- 24.4(2.3)
3 months	- 6.9(2.0)	- 9.6(2.3)	- 10.7(1.9)	- 6.4(2.3)
6 months	- 2.8(1.9)	- 8.8(2.1)	- 5.5(1.5)	- 3.8(2.0)
12 months	- 0.1(2.3)	- 3.2(2.4)	- 2.2(1.8)	- 0.3(1.7)

Suturing of flap to muscle and avoiding wound drainage can be performed to facilitate early discharge with no associated increase in surgical or psychological morbidity.

Mastectomy without Drain at Pectoral Area : a Randomized Controlled Trial

- Sixty patients underwent MRM
- Randomized to
 - Group I: only 1 drain was inserted at the axilla area
 - Group II: 2 drains were inserted into the pectoral area and axilla area
- ⇒ No differences in total drainage contents and complications

Special Considerations

- Level III dissection
- Intercostobrachial nerve
- Drain or no drain
- Seroma formation

Methods to Reduce Seroma Formation

- External compression dressing
(circumferential chest wrap of two 6-inch Ace bandages, held in place by circumferential Elastoplast bandage)
vs. Standard front-fastening Surgibra
- ⇒ Fails to decrease postoperative drainage and may increase the incidence of seroma formation after drain removal

Methods to Reduce Seroma Formation

□ Fibrin glue -Prospective randomized trials

⇒ significantly decrease the duration and quantity of serosanguinous drainage

Moore *et al.* J Am Coll Surg 2001

⇒ no significant benefit on axillary lymphatic drainage, drain removal time, or seroma formation

Berger *et al.* Breast Cancer Res Treat 2001

Ulusoy *et al.* Breast J. 2003

Methods to Reduce Seroma Formation

□ Immobilization of the affected arm

⇒ 5-day period of arm immobilization is **NOT** associated with decreased drainage and seroma in comparison with arm mobilization after the second postop. day

Petrek et al. Arch Surg 1990

⇒ No impact on the postoperative drainage volume and duration and is associated with discomfort and shoulder stiffness.

Christodoulakis *et al.* EJSO 2003

Methods to Reduce Seroma Formation

□ Octreotide

⇒ prospective randomized controlled trial
261 consecutive patients

⇒ Treatment group: 0.1 mg octreotide s.c.
3 times a day for 5 days

Control group: no treatment

⇒ Decreased amount and duration of seroma

Conclusion

- ❑ Patients with breast cancers should be informed of options available during treatment planning
- ❑ MRM remains an important tool for locoregional control of breast cancer
- ❑ Various methods to reduce postoperative complications remain inconclusive